



PATIENT

Rusty Orr

SPECIES

Canine

BREED

Labrador Mix

SEX

MN

AGE

13 years

WEIGHT

92 #

INTERPRETED BY

Remo Lobetti, BVSc,
MMedVet (Med), PhD,
Dipl. ECVIM

IMAGING PERFORMED BY

Lisa Bancroft, DVM

HOSPITAL NAME

Oakview Animal
Hospital

REFERRING VET

Dr Rowland

INVOICE

304079

DATE

4/5/23

PRESENTING CLINICAL SIGNS

History: Pollakiuria, intermittent hematuria.

Physical Examination: Prostamegaly.

Urinalysis: UTI.

CBC: N/A

Serum Biochemistry: N/A.

Radiographic Findings: Mineralized area at the bladder neck/prostate.

ULTRASONOGRAPHIC EXAMINATION OF THE ABDOMEN

Urinary System

Full urinary bladder with a normal thickness and appearance of the wall. Normal anechoic urine with no sediment or uroliths evident.

Normal trigone area, proximal urethra, and iliac blood vessels.

Iliac lymphadenomegaly (0.6 x 1.8 cm) with normal shape and echogenic appearance. Ureters not visualized.

Normal renal size (left 6.6 cm), echogenic appearance, cortico-medullary differentiation, pelvis, and capsule.

Reproductive System

Prostamegaly (5.2 cm) with a mottled echogenic and cavitatory appearance, foci of mineralization, and irregular capsule. Normal appearance of the peri-prostatic tissue.

Adrenal Glands

Left gland – enlarged (0.8/1.16 cm) with increased echogenic appearance, small focus of mineralization, and irregular capsule.

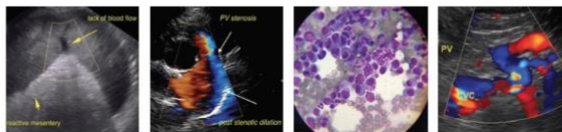
Right gland – irregular mottled echogenic mass (1 x 2.1 cm) with an area of mineralization at the caudal pole (1cm), and no obvious invasion into the surrounding vasculature.

Spleen

Normal size and echogenic appearance. Smooth homogenous parenchyma, regular capsule, and normal vasculature. No evidence of inflammatory, neoplastic, infarction, or infiltrative changes evident.

Liver

Normal size, echogenic appearance, portal markings, and regular curvilinear capsule. No nodules or masses evident.



PATIENT

Rusty Orr

SPECIES

Canine

BREED

Labrador Mix

SEX

MN

AGE

13 years

WEIGHT

92 #

INTERPRETED BY

Remo Lobetti, BVSc,
MMedVet (Med), PhD,
Dipl. ECVIM

IMAGING PERFORMED BY

Lisa Bancroft, DVM

HOSPITAL NAME

Oakview Animal
Hospital

REFERRING VET

Dr Rowland

INVOICE

304079

DATE

4/5/23

Gall bladder

Full gall bladder containing normal anechoic bile. Normal thickness and echogenic appearance of the gall bladder wall. Normal bile duct.

Gastrointestinal

Normal appearance of the gastro-esophageal junction, stomach, duodenum, small intestine, ileo-cecal junction, and colon with no loss of layering, normal wall thickness (jejunum 0.48 cm) and peristalsis, and no distension of the lumen.

Pancreas

Normal size (1.1 cm) and echogenic appearance. Regular capsule. Normal echogenic appearance of the mesentery and fat surrounding the pancreas.

Free Abdomen

No mesenteric lymphadenomegaly.
No ascites evident.

ULTRASONOGRAPHIC FINDINGS

Primary findings:

- Prostatic neoplasia.
- Left adrenomegaly.
- Right adrenal mass.
- Iliac lymphadenomegaly.

Secondary findings:

- None.

INTERPRETATION OF THE FINDINGS & FURTHER RECOMMENDATIONS

As the patient is neutered, the appearance of the prostate is typical for neoplasia with prostatitis an unlikely differential diagnosis.

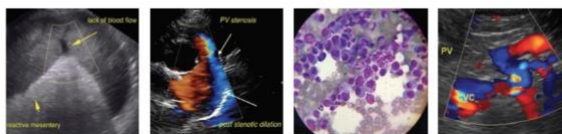
Etiologies for the left adrenal gland would be disease stress and Cushing's disease.

Etiologies for the right adrenal mass would be non-functional carcinoma, metastatic neoplasia from the prostate, and pheochromocytoma.

Etiologies for the Iliac lymphadenomegaly would be reactive and infiltrative neoplasia.

Further assessment that could be considered would be FNA cytology of the right adrenal mass and iliac lymph node, ACTH stimulation/LDDS suppression test, serial blood pressure, and urine/plasma catecholamine assay.

At this point palliative NSAID therapy for the prostate would be indicated.



PATIENT

Rusty Orr

SPECIES

Canine

BREED

Labrador Mix

SEX

MN

AGE

13 years

WEIGHT

92 #

INTERPRETED BY

Remo Lobetti, BVSc,
 MMedVet (Med), PhD,
 Dipl. ECVIM

IMAGING PERFORMED BY

Lisa Bancroft, DVM

HOSPITAL NAME

Oakview Animal
 Hospital

REFERRING VET

Dr Rowland

INVOICE

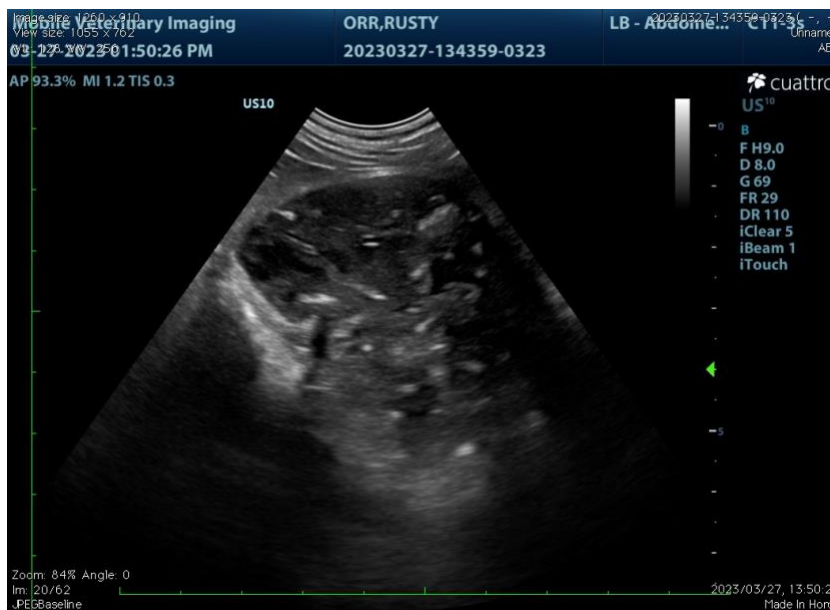304079

DATE

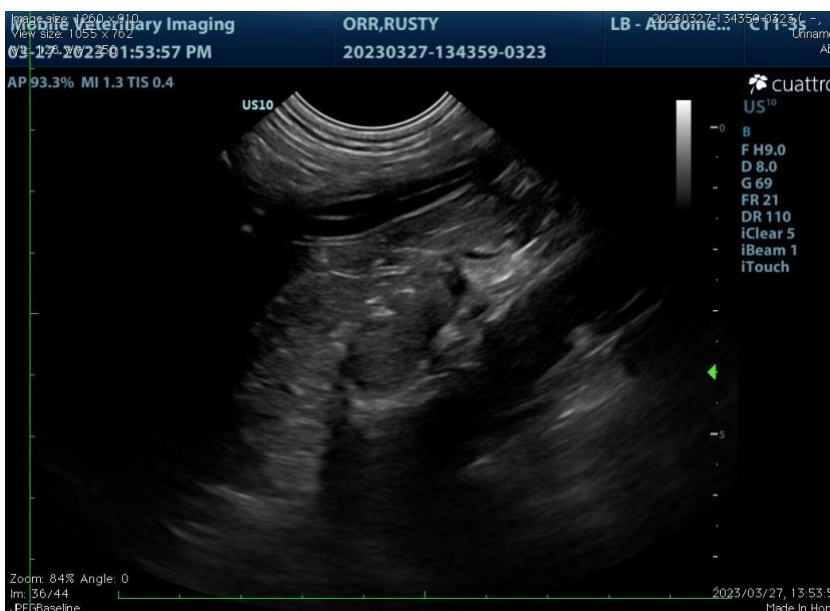4/5/23

IMAGES

Prostate



Left adrenal





PATIENT

Rusty Orr

SPECIES

Canine

BREED

Labrador Mix

SEX

MN

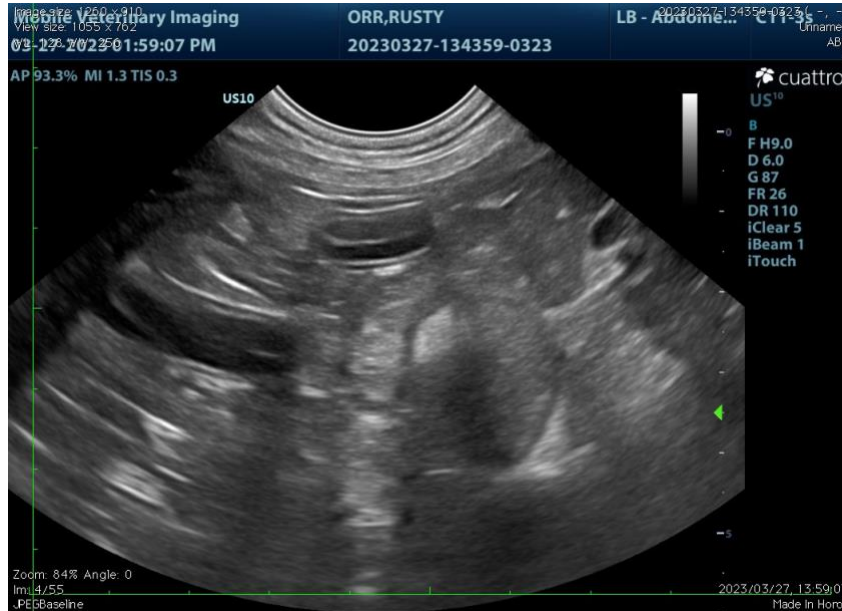AGE

13 years

WEIGHT

92 #

Right adrenal



INTERPRETED BY

Remo Lobetti, BVSc,
MMedVet (Med), PhD,
Dipl. ECVIM

The information and recommendations provided are based on the images presented by the referring veterinarian. No evaluation can be communicated regarding pathology that was not visible in the image/video clips provided.

Thank you for this referral. If the clinical or image interpretation does not parallel your findings or if I can be of any further assistance please contact me.

Remo Lobetti, BVSc, MMedVet (Med), PhD, Dipl. ECVIM (Internal Medicine)
rlobetti@mweb.co.za

IMAGING PERFORMED BY

Lisa Bancroft, DVM

HOSPITAL NAME

Oakview Animal
Hospital

REFERRING VET

Dr Rowland

INVOICE

304079

DATE

4/5/23